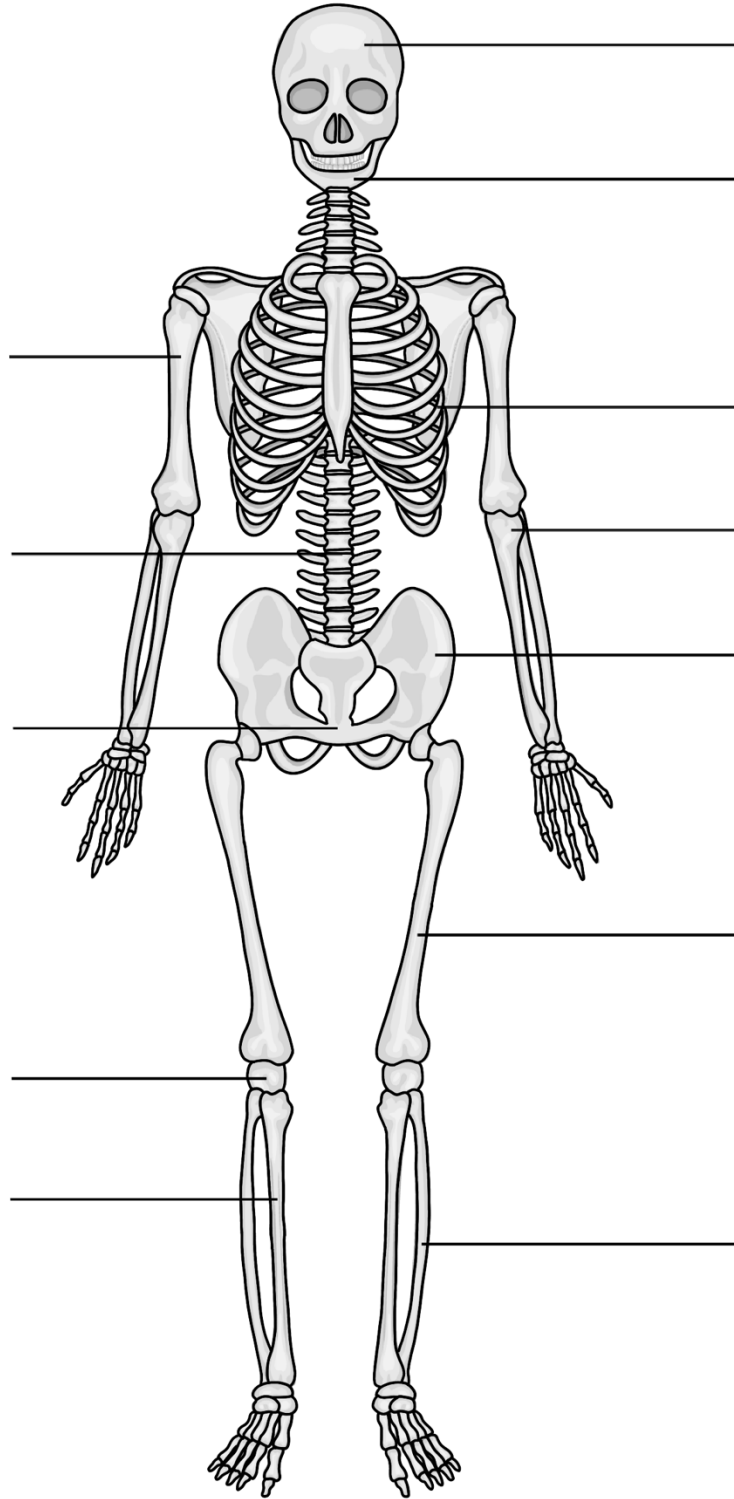


Human Skeletal System



scapula

femur

rib cage

patella

pelvis

radius

fibula

cranium

vertebrae

mandible

tibia

coccyx